

**PATIENT**

Maisie Larosa

**SPECIES**

Feline

**BREED**

Siamese

**SEX**

Female Spayed

**PRESENTING CLINICAL SIGNS**

History: Recurrent hyphema, Hypertension, Elevated Pro-BNP.

-Pertinent abnormal PE/Chem/CBC/UA Results: SDMA 15, CK 908, Pro-BNP 363.

-Systolic blood pressure 195mmHg with doppler 12/18/20. Systolic bp 154mmHg on 9/24/21.

-Current medications: Benazepril 1.8mg SID since 12/18/20. Amlodipine 0.625 SID started 9/24/21.

-Sedation used: Not needed.

-STAT: Not requested.

**ECHOCARDIOGRAM FINDINGS**

2D, m-mode, color flow and doppler imaging is available. The left ventricular wall is remodeled with a focal septal bulge. The remainder of the LV wall measures normal. There is a diffusely hyperechoic endocardium consistent with fibrosis. The papillary muscles are mildly remodeled and hyperechoic. The endocardium also appears remodeled. The left atrium is normal in size. The right atrium is normal in size. The right ventricle appears normal. The mitral valve is normal in structure and mobility. Trace TR. Blood flow through both the LVOT and RVOT is normal in velocity. No pleural or pericardial effusion seen. No obvious cardiac tumors.

**CARDIAC CHART**

**AGE**

2007

**WEIGHT**

8lbs

**INTERPRETED BY**

Maggie Machen  
Lamy, DVM, DACVIM  
(Cardiology)

**HOSPITAL NAME**

Timonium Animal  
Hospital

**REFERRING VET**

Dr. Stephens

**INVOICE**

21557

**DATE**

10/15/21

FELINE CARDIAC PARAMETERS	BODY WEIGHT (kg)	HR (BPM)	IVSd (cm) (Moise, Pipers)	LVIDd (cm) (Moise, Pipers)	LWVd (cm) (Moise, Pipers)	FS (%)	EF (%)
NORMAL PARAMETER	-----	150-240	3.5-0.55	<2 (mean 1.5)	3.5-0.55	35-67	80-100
PATIENT	3.6	182	0.36	1.4	0.34	40	74
FELINE CARDIAC PARAMETERS	LA/AO (Boon)	LA/AO HEART BASE (Swe) (Abbott)	LA 2D short axis Base view (cm) (Abbott)		LVOT VEL (m/s)	RVOT VEL (m/s)	E max (m/s)
NORMAL	<1.5	<1.3	<1.2		<1.6	<1.3	<0.9
PATIENT	NM	1.0	1.0		1.1	0.76	NM

Adapted from June Boon, Veterinary Echocardiography, 1998  
Abbott J & MacLean H JVIM 2006;20: 111-119, Moise et al. Am J Vet Res 47:1476, 1986. Pipers et al. Am J Vet Res 40:882, 1979.

### INTERPRETATION OF THE FINDINGS & FURTHER RECOMMENDATIONS

Focal LV hypertrophy is present in addition to LV remodeling, which may be indicative of early hypertrophic disease or may simply represent a normal variant. The history of systemic hypertension may or may not be related to this finding and follow up is advised once the blood pressure is well controlled. Certainly, there is no evidence of severe chronic pressure overload of the left heart which is a good sign. The LA is normal indicating low risk at this time.

Continued treatment/evaluation of systemic hypertension is recommended, including screening for underlying causes. Consultation with an Internal Medicine Specialist may be useful if difficult to control.

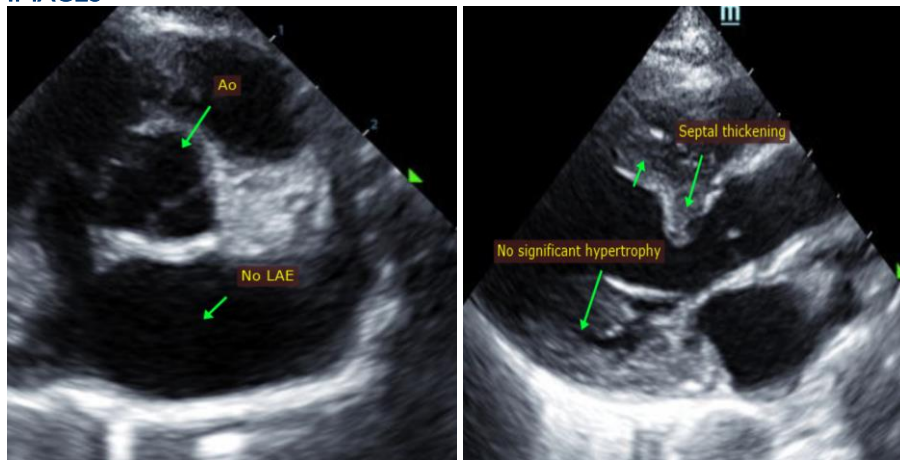
Given a normal LA dimension, no medications are indicated.

Anesthetic risk is mild, however any cat with this degree of fibrosis and diastolic dysfunction will be at risk for iatrogenic IV fluid overload should they be needed in the future.

Monitor for any development of clinical signs, including labored breathing or signs of a blood clot (paralysis, neurologic change).

A recheck echocardiogram is recommended in 6-12 months to screen for any evidence of progression, sooner if clinical signs arise.

### **IMAGES**



**The information and recommendations provided are based on the images presented by the referring veterinarian. No evaluation can be communicated regarding pathology that was not visible in the image/video clips provided.**

Thank you for this referral. This report was generated using transcription software, and minor dictation errors may be present. If the clinical or image interpretation does not parallel your findings or if I can be of any further assistance, please contact me.

**Maggie Machen Lamy, DVM**  
**Diplomate of the American College of Veterinary Internal Medicine (Cardiology)**  
**info@sonopath.com**